



PATIENT

Didymus Allen

SPECIES

Canine

BREED

Chihuahua

SEX

Male Neutered

AGE

8 years

WEIGHT

9.81lbs

INTERPRETED BY

Maggie Machen
Lamy, DVM
DACVIM (Cardiology)

IMAGING PERFORMED BY

Pamela Harrigan,
RDCS

HOSPITAL NAME

Mass Veterinary Services

REFERRING VET

Dr. Masloski

INVOICE

23874

DATE

4/26/22

PRESENTING CLINICAL SIGNS

History: Didymus was noted to have a heart murmur in January. No coughing but does occasionally sneeze and will have some gastroenteritis (V/D) when stressed. Didymus is eating well and maintains a normal activity level. On exam: NSR, grade I-II/VI murmur with PMI left apical area, PSS, lung fields clear. BP: 240mmHg x 5 (stressed). No medications. *Sedated with propofol for study.

ECHOCARDIOGRAM FINDINGS

2D, m-mode, color flow and Doppler imaging is available.

Left ventricle: The LV diameter is normal with adequate myocardial function. LV wall thicknesses are normal. A small (0.33cm) perimembranous VSD is visualized with complete aneurysmal closure (no flow across the defect).

Left atrium: The left atrium is normal.

Mitral valve: The mitral valve is diffusely thickened with no prolapse into the left atrial lumen. Mild eccentric mitral regurgitation with a normal velocity.

Aortic valve/aorta: The aortic valve is normal in morphology and mobility. Normal aortic outflow velocity; laminar flow. No aortic insufficiency.

Right ventricle: Normal right ventricular diameter and morphology indicating no overt evidence of pulmonary arterial hypertension.

Right atrium: Normal RA dimension.

Tricuspid valve: The tricuspid valve appears normal with no tricuspid regurgitation.

Pulmonic valve/pulmonary artery: The pulmonic valve is normal in morphology and mobility. No pulmonic insufficiency. Normal RVOT velocity; laminar flow.

Pericardium/other: No pericardial or pleural effusion noted. No obvious cardiac masses.

Heart rhythm: ECG reveals a sinus rhythm with an average HR of 160bpm.

2-Dimensional Measurements

Ao diam (cm)	1.2
LA diam (cm)	1.4
LA:Ao (Swe)	1.2
IVS thickness (cm)	0.66
LVID diastole (cm)	1.7
PW thickness (cm)	0.67
LVID systole (cm)	0.9
FS (%)	47

Doppler Measurements

PV Vmax (m/s)	0.8
AoV Vmax (m/s)	1.2
MR Vmax (m/s)	4.3
TR Vmax (m/s)	NA
TR PG (mmHg)	NA

INTERPRETATION OF THE FINDINGS

The cause of the murmur is chronic degenerative valve disease causing mild mitral regurgitation. Lack of significant left atrial enlargement indicates the current risk for complication is low. As an incidental finding, a small VSD is identified with an aneurysmal membrane. The membrane is providing complete closure with no flow across the defect. No additional issues are noted in this study.

Assessment of progression in the future will help predict long term prognosis, which is highly variable at this stage (B1).

The reported blood pressure is elevated and should be reassessed for accuracy particularly given no reported clinical signs of severe hypertension (retinal changes, etc.) or evidence of LVH on echo. Ideally obtain serial measurements in a controlled, low stress environment and continue until 3 consecutive readings plateau within 5mmHg of variability. If persistently >180mmHg despite a relatively calm demeanor, recommend



PATIENT
Didymus Allen

institution of amlodipine to effect. Additionally, if deemed accurate, screening for predisposing underlying causes of SHT is recommended (Cushings, PLN, adrenal tumor, etc.), as primary disease is relatively uncommon and a rule out diagnosis.

SPECIES
Canine

BREED
Chihuahua

- RECOMMENDATIONS**
- In a dog without significant left atrial enlargement, no cardiac medications are clearly indicated.
 - Reassess BP as discussed.
 - Omega fatty acid supplementation and mild salt restriction may be of some long-term benefit.
 - Anesthetic risk is considered mild if needed. Cardiac protective drug choices (opioid/benzodiazepine premedication, propofol or alfaxalone induction, isoflurane gas) are recommended. Pre-oxygenate for 5-10 minutes prior to induction. Monitor for arrhythmias, hypotension, and hypoxia both intra and post-operatively and intervene as necessary. Mild IV fluid restriction is recommended to avoid fluid overload. Avoid heart rate stimulating drugs such as atropine unless clinically indicated.
 - Monitor for development of a cough, labored breathing, exercise intolerance or collapse episodes.

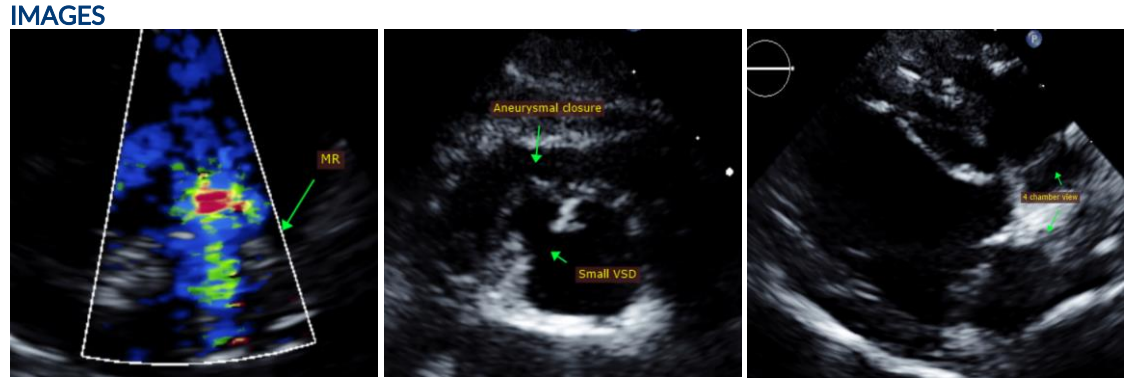
SEX
Male Neutered

AGE
8 years

WEIGHT
9.81lbs

- PLAN**
- Recommend conservative monitoring with a recheck echocardiogram in 6 months, sooner if any development of clinical signs.

INTERPRETED BY
Maggie Machen Lamy, DVM
DACVIM (Cardiology)



IMAGING PERFORMED BY
Pamela Harrigan, RDCS

HOSPITAL NAME
Mass Veterinary Services

The information and recommendations provided are based on the images presented by the referring veterinarian. No evaluation can be communicated regarding pathology that was not visible in the image/video clips provided.

REFERRING VET
Dr. Masloski

Thank you for this referral. This report was generated using transcription software, and minor dictation errors may be present. If the clinical or image interpretation does not parallel your findings or if I can be of any further assistance, please contact me.

INVOICE
23874

Maggie Machen Lamy, DVM
Diplomate of the American College of Veterinary Internal Medicine (Cardiology)
info@sonopath.com

DATE
4/26/22

Echocardiogram performed by: Pamela Harrigan, RDCS
Pet Animal Ultrasound Service (4paus.com)